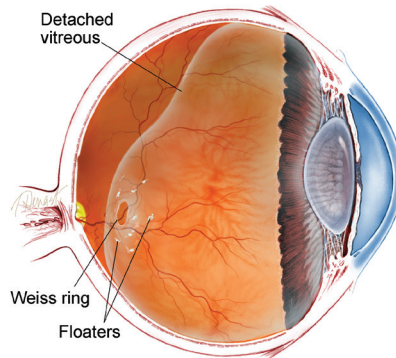


**Vitrectomy for Floaters** As we get older, some of us may see “floaters” in our field of vision. In rare cases when many of these floating specks interfere with vision while driving or reading, one treatment option is **vitrectomy**—surgical removal of the eye’s vitreous gel.

**Causes:** The vitreous gel is attached to the retina at birth. At some point, as a natural part of aging, the vitreous pulls free from the retina. This **posterior vitreous detachment** is the most common cause of floaters. Blood, inflammatory cells, or pigment cells may also collect in the vitreous cavity (see risk factors) and lead to floaters.



**Risk Factors:** There are many risk factors for vitreous floaters, including:

- Nearsightedness
- Retinal tear
- **Retinal detachment**
- Intraocular inflammation
- **Vitreous hemorrhage**
- Trauma

Previous cataract surgery can increase the perception of floaters.

**Diagnostic Testing:** Vitreous opacities—the cause of symptomatic floaters—are detected by clinical examination with pupil dilation. This is the most valuable and reliable way to observe floaters that a patient is seeing.

Other ways to evaluate floaters include **optical coherence tomography (OCT)**, **B-scan ultrasound**, and retinal photography.

**Treatment and Prognosis:** A decision to treat is based on patient complaints, symptoms, and exam findings. If a patient complains of floaters, but these cannot be confirmed on clinical exam, the need for surgery would be brought into question. On the other hand, some patients have severe vitreous opacities visible on exam, but have no symptoms. Both of these groups of patients are generally observed without intervention.

Many patients with mild floaters who are bothered can be persuaded to learn to ignore the finding. Reassurance from a physician that the floaters have been evaluated and raise no threat to vision can be very helpful.

However, some patients have vitreous opacities serious enough to consider surgical removal. These cases include those with extensive particles or clouds of debris in the vitreous cavity that move in and out of vision. These patients complain of the feeling that they cannot read continuously, or that as they are driving a car, the cloud moves in front of their vision and they nearly have to pull over for fear of having an accident.

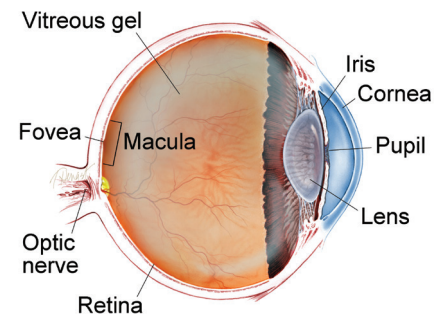
## SYMPTOMS

The **vitreous** is a normally clear gel that occupies the rear cavity of the eye. With aging, the gel may develop opacities (unclear areas) and movement, creating the sensation of bugs or dirt in the vision due to shadows cast onto the retina.

Patients can see these “floaters” especially against a bright background like a blue sky or a white wall. Many people have an occasional floater, and once this has been evaluated to rule out a **retinal tear**, this symptom can be safely ignored.

Many patients with floaters find that, over several months, the symptoms decrease and the sensation becomes more tolerable. However, some develop extensive floaters that do not subside. ●

## WHAT IS THE RETINA?



**THE RETINA** is a thin layer of light-sensitive nerve tissue that lines the back of the eye (or vitreous) cavity. When light enters the eye, it passes through the iris to the retina where images are focused and converted to electrical impulses that are carried by the optic nerve to the brain resulting in sight.

*continued next page*

## Vitreotomy for Floaters

*continued from previous page*

Outpatient surgery with local anesthesia can be utilized during vitrectomy to remove floaters and vitreous debris. During this procedure, nearly all the vitreous is removed, and with it, almost all of the vitreous opacities.

Risks associated with vitrectomy include, but are not limited to, **cataract** formation, retinal tear and detachment, **macular pucker**, and **macular edema** (swelling). There is a small risk of vision loss.

A laser is now available that can be used to try to break up large floaters into particles small enough to be ignored. Randomized clinical trials are underway to determine the safety and effectiveness of this procedure. The Internet has many ads from eye care centers offering this treatment; however, this laser has yet to gain wide acceptance. ●

### Clinical Terms *(appearing green within fact sheet text)*

**Dynamic B-scan ultrasound:** Sound waves are used to form an image of the back of the eye during ocular movements. This allows identification of spatial relationships of structures within the eye.

**Cataract:** A clouding of the eye's lens causing a decrease in vision. Cataracts are the most common cause of vision loss for those over the age of 40.

**Floater:** Mobile blurry shadow that partially obscures vision. Floaters are most bothersome when near the center of vision and less annoying when they settle to the side of the vision. They may appear like cobwebs, dust, or a swarm of insects--or in the shape of a circle or oval, called a Weiss ring.

**Macular edema:** The term used for swelling in the macula in eyes, or the center part of the retina which is responsible for providing the sharp, straight-ahead vision used for reading and recognizing faces as well as color vision.

**Macular pucker:** An epiretinal membrane is a layer of scar tissue that forms over the macula that reduces vision and can warp and contract causing a wrinkling of the retina known as macular pucker.

**Optical coherence tomography (OCT):** A non-invasive imaging technique that uses light to create a 3-dimensional image of your eye for physician evaluation.

**Posterior vitreous detachment (PVD):** A natural change that occurs during adulthood, when the vitreous gel that fills the eye separates from the retina, which is the light-sensing nerve layer at the back of the eye responsible for sight.

**Retinal detachment:** A condition where the retina separates from the back of the eye cavity. This may be caused by vitreous gel or fluid leaking through a retinal tear or hole and collecting under the retina causing it to separate from the tissue around it.

**Retinal tear:** A rip or discontinuity in the retina, which is the thin layer of light-sensitive nerve tissue that lines the back of the eye and is responsible for sight.

**Vitreotomy surgery:** A procedure undertaken by a specialist where the vitreous gel that fills the eye cavity is removed to provide better access to the retina. This allows for a variety of repairs, including the removal of scar tissue, laser repair of retinal detachments and treatment of macular holes. Once surgery is complete, saline, a gas bubble or silicone oil may be injected into the vitreous cavity to help hold the retina in position while the eye heals.

There are different types of vitrectomy:

- Pars plana vitrectomy is performed by retina specialists to address diseases of the 'posterior' (back) segment of the eye cavity, also referred to as the pars plana.
- Anterior vitrectomy is performed by ophthalmologists or retina specialists to address leakage of vitreous gel into the front (anterior) chamber of the eye.

**Vitreous hemorrhage:** A leakage of blood into the gel that fills the eye cavity (also called vitreous humor) that is often the result of blockage or damage to blood vessels in the retina.

**Vitreous or vitreous humor:** The "gel" that fills the inside of the eye or vitreous cavity.

### THANK YOU TO THE RETINA HEALTH SERIES AUTHORS

Sophie J. Bakri, MD  
Audina Berrocal, MD  
Antonio Capone, Jr., MD  
Netan Choudhry, MD, FRCS-C  
Thomas Ciulla, MD, MBA  
Pravin U. Dugel, MD  
Geoffrey G. Emerson, MD, PhD  
Roger A. Goldberg, MD, MBA  
Darin R. Goldman, MD  
Dilraj Grewal, MD  
Larry Halperin, MD  
Vincent S. Hau, MD, PhD  
Suber S. Huang, MD, MBA  
Mark S. Humayun, MD, PhD  
Peter K. Kaiser, MD  
M. Ali Khan, MD  
Anat Loewenstein, MD  
Mathew J. MacCumber, MD, PhD  
Maya Maloney, MD  
Hossein Nazari, MD  
Oded Ohana, MD, MBA  
George Parlitsis, MD  
Jonathan L. Prenner, MD  
Gilad Rabina, MD  
Carl D. Regillo, MD, FACS  
Andrew P. Schachat, MD  
Michael Seider, MD  
Eduardo Uchiyama, MD  
Allen Z. Verne, MD  
Yoshihiro Yonekawa, MD

### EDITOR

John T. Thompson, MD

### MEDICAL ILLUSTRATOR

Tim Hengst